



Computed Tomographic Anatomy and Topography of the Lower Respiratory System of the European Pond Turtle (*Emys Orbicularis*)

Omid Zehtabvar¹, Zahra Tootian¹, Alireza Vajhi*², Bahador Shojaei³, Amir Rostami⁴, Somaye Davudypoor², Javad Sadeghinezhad¹, Hanyeh Ghaffari⁵, Iman Memarian⁶

Abstract

Objective- This study was done to give complete topographic information about the position of the lungs and trachea in European pond turtle using Computed Tomography (CT) and usual anatomic methods.

Design- Experimental study

Animals- 10 female, adult European pond turtles (*Emys orbicularis*)

Procedures- All scans were obtained on a two detector scanner. In anatomical study eight turtles were dissected. Two other turtles were sectioned transversely.

Results- Our results showed some differences in the tracheal length, position and bifurcation site with that of other species. Moreover the topography of the lungs is described in retracted and protruded neck in this article.

Conclusion and Clinical Relevance- Most of vital systems, lungs and coelomic part of the trachea, are enclosed by the carapace and the plastron so it can not be examined customarily by clinicians. The noninvasive diagnostic imaging techniques provide detailed information concerning these organs. The general morphological features of the lower respiratory system of the European pond turtle were examined by CT images and macroscopically in this study. We found some important dissimilarities with other species.

Key Words- CT, Anatomy, Topography, Lung, Trachea, *Emys orbicularis*

Introduction

Turtles in north of Iran, belong to the Emydidae family and consist of Caspian pond (*Mauremys caspica*) and European pond turtle. The European pond turtle territory is limited to Caspian sea and provinces of Golestan, Mazandaran and Ardebil.¹ Reptiles, especially turtles who inhabit both on land and water, have made some special adaptations, namely in their respiratory system. Many people keep turtles as pets. Therefore, the

anatomic knowledge of turtles should be more carefully evaluated and used for therapeutic purposes. Respiratory system is one of the most important body systems which is assessed at the time of patient routine examinations.^{2, 3} Most of this system, lungs and coelomic part of the trachea, are enclosed by the carapace and the plastron so it can not be examined customarily by clinicians. According to the anatomic differences of turtles with that of more common pets, routine examination methods and Computed Tomography (CT) images of the other small animals can not be used for evaluation of their internal organs.^{4, 5} In these instances the noninvasive diagnostic imaging techniques provide detailed information concerning these organs.⁶ Computed Tomography makes precise anatomic data which can be used as a reference for comparing with the images of the abnormal cases. On the other hand, knowledge of the topographic anatomy of the respiratory system is essential for using various diagnostic imaging techniques. Combination of these modalities has been done in some turtles⁶ to have a complete imagination of the situation and neighboring

¹Department of Basic Science, Faculty of Veterinary Medicine, University of Tehran, Tehran, Iran.

²Department of Surgery and Radiology, Faculty of Veterinary Medicine, University of Tehran, Tehran, Iran.

³Department of Basic science, Faculty of Veterinary Medicine, Shahid Bahonar University of Kerman, Kerman, Iran.

⁴Department of Internal Medicine, Faculty of Veterinary Medicine, University of Tehran, Tehran, Iran.

⁵Department of Environment, Faculty of Natural Resources, University of Kurdistan, Sanandaj, Iran.

⁶Wildlife Veterinarian, Chief Veterinarian of Tehran zoo and Pardisan Rehabilitation Centre, Tehran, Iran

Address all correspondence to Dr. Alireza Vajhi (DVM, DVSc), E-mail: avajhi@ut.ac.ir

of the respiratory system. This study was done to give complete topographic information and knowledge about the position of the lungs and trachea in European pond turtle using CT and usual anatomic methods. Normal CT appearance of lungs and gathering practical anatomy tips were among the other goals of this study.

Materials and methods

Animals

In this study, 10 female, adult European pond turtles with the mean weight of 350 grams and mean plastron length (ventral part of the shell) of 18 centimeters were selected. The turtles were caught live from the ponds of Gilan province and were transported to the Veterinary Faculty of University of Tehran. These turtles were kept under the proper conditions, suited for reptiles and fed whole Kilka fish.⁷

CT Examination

Each turtle was medicated with ketamine (10% alfasan, 25 mg/kg, intramuscular) and diazepam (10mg/2ml caspian, 1 mg/kg, intramuscular). All turtles were positioned in Ventral recumbency, and all scans were obtained on a two detector scanner (Siemens Somatom Spirit) vertical to the longitudinal axes of the animal. The scanning parameters were as follow: rotation time, 1 s; slice thickness, 1mm; reconstruction interval, 0.5–1 mm; pitch, 1; X-ray tube potential, 120 kV; and X-ray tube current, 100 mA. All helical scans were started at the tip of the mandible and covered the entire respiratory system. All CT images were reviewed on a dedicated computer workstation. Images were examined in both lung and bone windows, with window width (WW) and window level (WL) adjusted to personal preferences (for different parts) and 3D reconstruction images was also reviewed in pulmonary pattern for further investigation and more thorough study of the respiratory system. The length of the trachea and left and right bronchus were measured. The images were taken in both flexion and extension of the neck and limbs.

Anatomic Examination

After CT examination cases were euthanized for medical reasons unrelated to diseases of the respiratory system. The carapace-plastron junction of the eight turtles was cut by the pin cutter. Muscles attachment to plastron was severed and the lungs and trachea were evaluated. Air was injected at the proximal part of the trachea to evaluate the structure of the lungs and trachea. For measuring the length of the trachea and left and right bronchus, a digital caliper was used. Two other turtles were fixed by 10% Formaldehyde and were sectioned transversely. CT images were compared with

the sections and were labeled according to anatomic assessment.

Statistical Analysis

The data was analyzed with SPSS 16 software and Pair sample T method, a probability value ($P < 0.05$) was considered statistically significant.

Results

CT Scan Analysis

The topography of the trachea and lungs in the protruded neck

In the protruded neck position of the animal, the trachea started from the glottis in the midline and continued caudally. After a short distance, the trachea made a dorsal flexion between the base of the head and the first cervical vertebra. After that, the trachea inclined into the left side of the neck from the third cervical vertebra and entered to the coelomic cavity. The trachea bifurcated into two principle bronchi above the acromial process of the left scapula at the level of the eight-ninth vertebrae. The left bronchus continued dorsally to enter into the left lung (immediately after caudal border of the third rib) but the right one coursed ventrally to enter the right lung (a little caudally than the left bronchus). It is notable that the right bronchus arched ventral to the neck due to the left side positioning of the bifurcation of the trachea (Fig 1). As a result, the length of the right bronchus (1.90cm) was significantly more than the left one (1.37cm) ($p < 0.05$). Each bronchus bifurcated into the dorsal and caudal branches inside the lung (Fig 4). The bifurcation occurred at the level of the caudal border of the third rib. The bifurcation of the right bronchus was seen a little caudally in comparison to the left one (Fig 3). It should be stated that in many cases the dorsal branch itself bifurcated into the cranial and caudal branches. Its two branches were adjacent to the dorsal surface of the lung and in some cases were at the level of the dorsal surface (Fig 4). According to the CT number of the pulmonary vessels, they could be easily evaluated by their parallel position with that of air ways (Fig 5,6).

The main part of the lung extended from the shoulder to the pelvic girdles. Each lung possessed a small cranial part (apex) which extended on the medial side of the scapula beyond the first rib. The apex extended a little cranially in the right lung more than the left one. The main part of the lungs flattened from the second to the sixth ribs and then narrowed at the level of the sixth rib caudally. The caudal borders of the lungs were observed at the level of the cranial border of the tenth ribs (Fig 3). In some specimens the left lung situated more caudally than the right and in the others this extension was seen in an opposite situation. Caudal to the apices, the medial

borders of the lungs were seen parallel and close to each other between the second and seventh ribs. Further than they got away from each other caudally.

The topography of the trachea and lungs in the retracted neck

In comparison with the protruded neck, the bifurcation of the trachea replaced caudally and was observed at the third rib on the left side in the retracted neck position. It is important to note that in over flexion of the neck, the bifurcation shifted to the level of the fourth rib (Fig 2).

By this shifting the route of bronchi changed from the craniocaudal direction to the caudocranial one (Fig 4). However the level of the principle bronchi entrance to the lung showed no change (Fig 3). Through the retraction, the neck occupied the space between the medial borders of the main parts of the lungs (Fig 3). This replacement affected the lungs how their apices displaced ventrolaterally (Fig 4), and their medial borders got away (Fig 3). In some cases in which the over flexion of the pelvic limbs occurred the caudal extremity of the lungs replaced cranially.

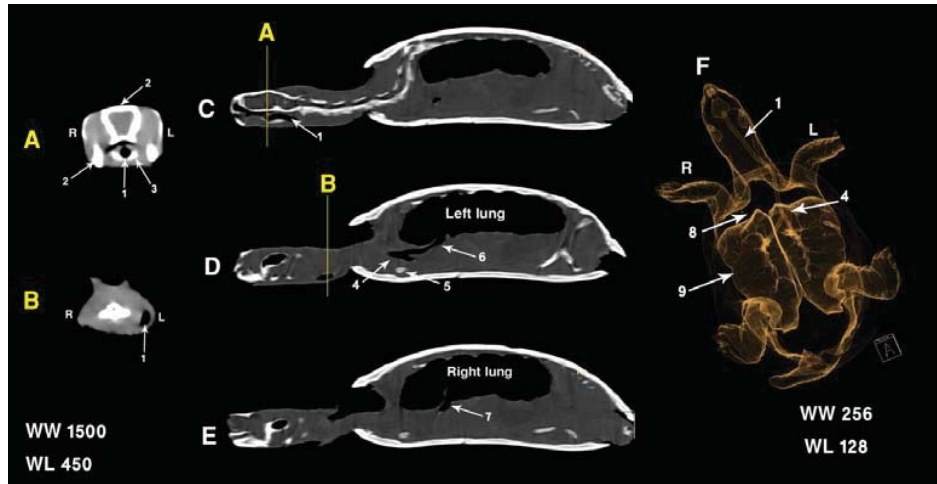


Figure 1- (A,B) Computed tomography images of the *Emys orbicularis*, transverse plane – bone window, (C-E) Computed tomography images, median (C), left paramedian (D), right paramedian (D) plane – bone window, (F) 3D reconstruction image (pulmonary pattern). 1. Trachea, 2. skull, 3. hyoid apparatus, 4. tracheal bifurcation, 5. acromion process of scapula, 6. left bronchus, 7. right bronchus, 8. apex of the right lung, 9. main part of the right lung.

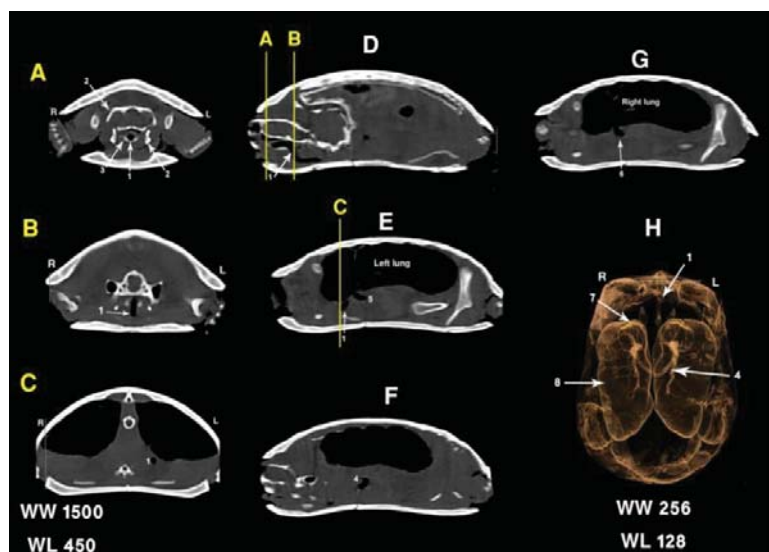


Figure 2- (A-C) Computed tomography images of the *Emys orbicularis*, transverse plane – bone window, (D-G) Computed tomography images, median (D), left paramedian (E,F), right paramedian (G) planes – bone window, (H) 3D reconstruction image (pulmonary pattern). 1.trachea, 2. skull, 3. hyoid apparatus, 4. tracheal bifurcation, 5. left bronchus, 6. right bronchus, 7. apex of the right lung, 8. main part of the right lung.

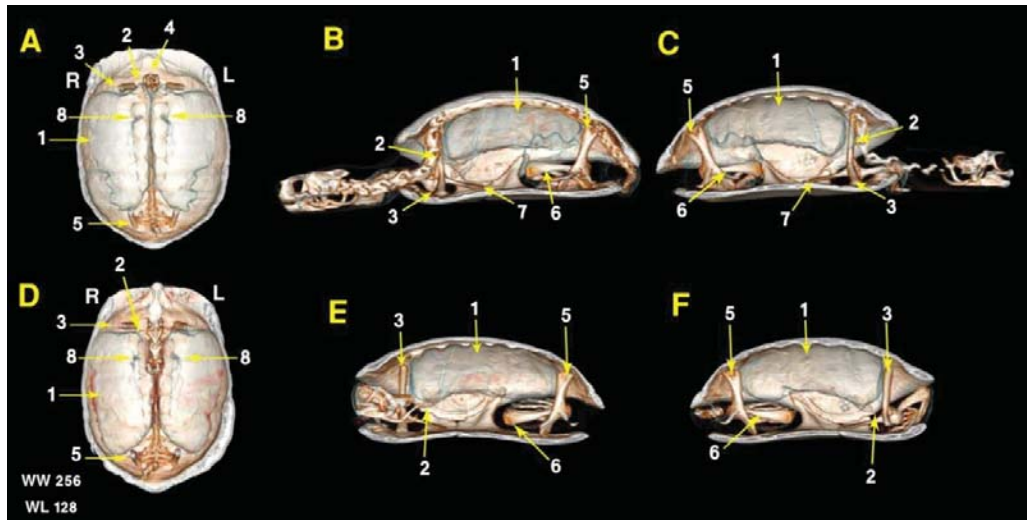


Figure 3- 3D reconstruction images (Pulmonary Vascularization) of the *Emys orbicularis*, shows bones and respiratory system, (A,D) frontal section, (B,E) right paramedian section, shows right lung, (C,F) left paramedian section, shows left lung, In A,B,C images limbs and neck are extended, in D,E,F images limbs and neck are flexed. 1. main part of the lung, 2. apex of the lung, 3. scapulla, 4. vertebral column, 5. ilium, 6. femur, 7. Coracoids bone, 8. bifurcatin of the bronchus

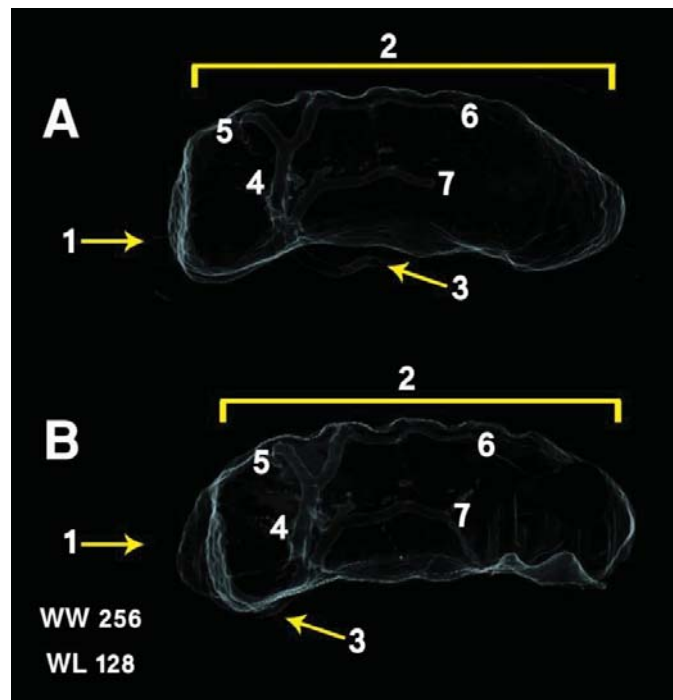


Figure 4- 3D reconstruction images (Pulmonary) of the *Emys orbicularis*. Shows lung and bronchus, (A) neck and limbs are flexed, (B) neck and limbs are extended 1.apex of the lung, 2. main part of the lung, 3. bronchus, 4. dorsal branch of the bronchus, 5. caudal branch of the bronchus, 6. cranial part of the dorsal branch of the bronchus, 7. caudal part of the dorsal branch of the bronchus.

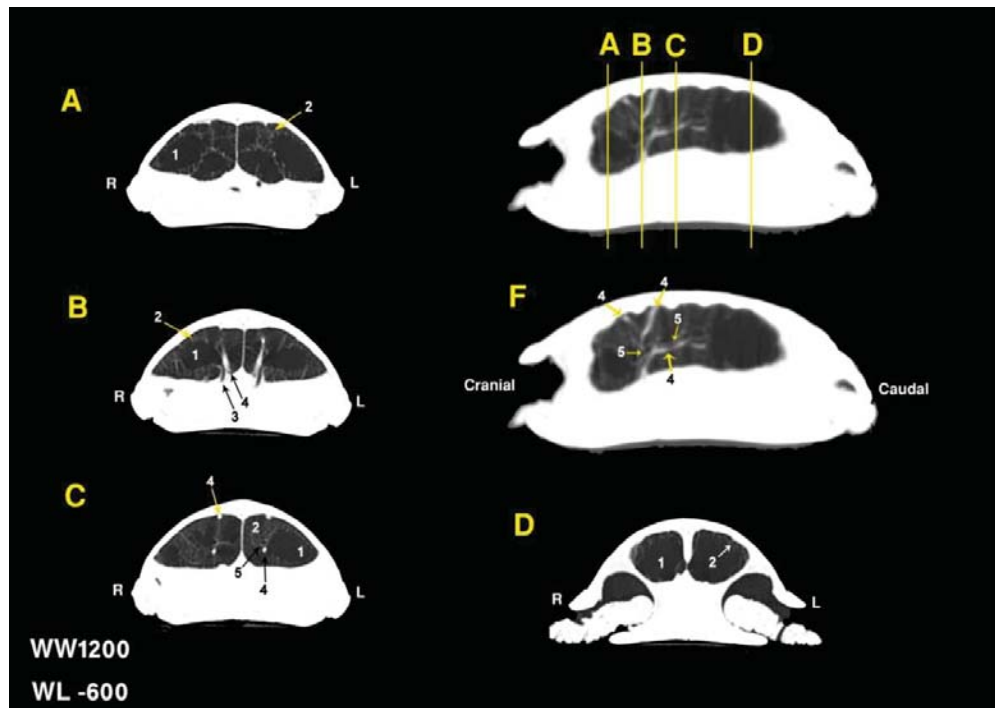


Figure 5- (A-D) Computed tomography images of the *Emys orbicularis*, transverse plane – lung window, (F) right paramedian plane – lung window. 1. lung lumen, 2. lung parenchyma, 3. bronchus, 4. blood vessel, 5. caudal branch of the bronchus.

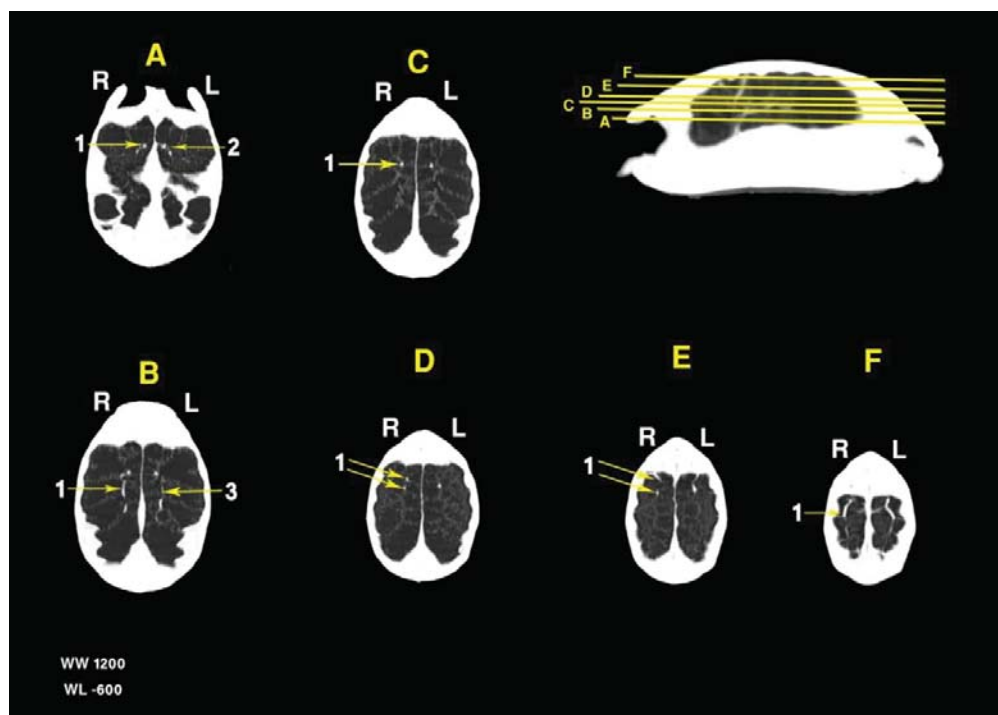


Figure 6- (A-F) Computed tomography images of the *Emys orbicularis*, Dorsal planes – lung window. 1. blood vessel, 2. bronchus, 3. caudal branch of the bronchus, 4. blood vessel, 5. caudal branch of the bronchus.

Anatomy Study

Anatomic results showed that the trachea was composed of the complete cartilaginous rings. Its average length was measured about 6.65cm. The proximal part of the trachea was observed at the ventral side of the oesophagus. At the level of the third cervical vertebra, it replaced to the left side of the neck and continued caudally by this position to the bifurcation site. The tracheal bifurcation situated in the left side of the neck within coelomic cavity (Fig7). It was interestingly moved to the cranial and caudal with the protrusion and retraction of the neck respectively. This moving results in the change of the bronchi routes which mentioned in the CT results part. Beyond the tracheal bifurcation, the left bronchus was accompanying by the oesophagus. The right and left bronchi coursed 1.925 and 1.39cm before entering the respective lungs. The difference in the length mean of the bronchi was significant ($p < 0.05$). The paired pinkish lungs attached to the carapace dorsally and were in contact with the visceral organs ventrally (Fig9). In some areas the lungs replaced deeply and were seen at a superficial position after removing of the ventral body wall and pectoral girdles (Fig8). Their cranial and caudal boundaries were shoulder and pelvic girdles respectively. Alveolar structures had given a special feature to the external surface of the lungs (Fig8). No lobation was seen in the lungs, but in the transverse sections some septa had divided each lung into smaller chambers which their internal walls showed reticular formation (Fig9). The retracted neck was observed caudally between the cranial third of the two lungs.

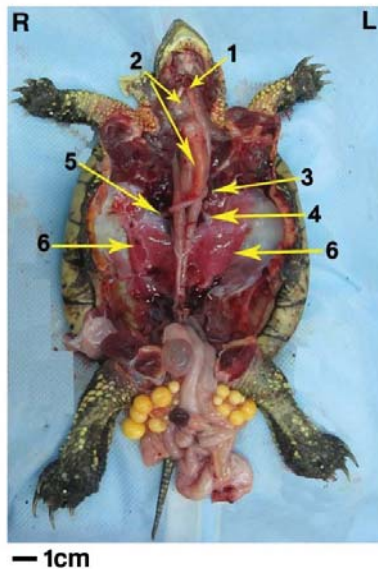


Figure 7- Dorsal recumbency of the *Emys orbicularis*. Plastron, viscera except respiratory system, pectoral and shoulder girdles are removed. 1. trachea, 2. oesophagus, 3. tracheal bifurcation, 4. left bronchus, 5. right bronchus, 6. lung.

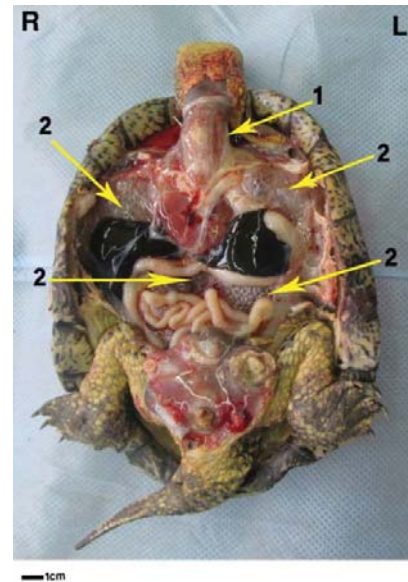


Figure 8- Dorsal recumbency of the *Emys orbicularis*, Plastron, shoulder girdles and fore limbs are removed. 1. trachea, 2. lung.

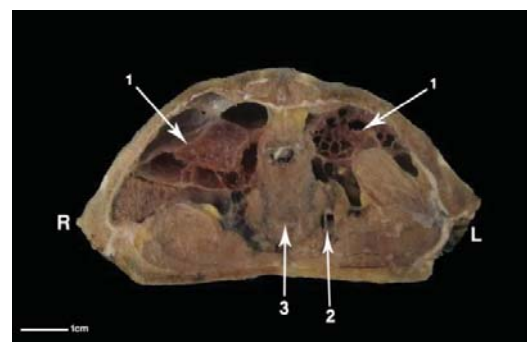


Figure 9- Transverse section between the third and fourth ribs of the *Emys orbicularis*. 1.lungs, 2.trachea, 3.neck.

Discussion

The general morphological features of the lower respiratory system of the European pond turtle were examined in this study. They were in accordance with those described for chelonians, with some differences. The trachea has been reported to have a variable route and position in different species. In the *Caretta caretta* the trachea is ventral and to the right of the oesophagus.⁶ It has been reported that in cryptodira species the trachea is very short and bifurcates rapidly to allow the head and neck to retract.⁸ The position of the carina found in the aquatic species appear to be slightly more caudal than in land tortoises, in which the trachea bifurcates after coursing a relatively short distance down the neck.⁹ In tortoises and most turtles (Cryptodira) the neck vertebrae flex vertically, allowing the head to be drawn straight back within the shell. In

these species the most cranial position of the carina allows breathing even when the head and neck are withdrawn.¹⁰ It has been reported that in sea turtles the ability to retract the head has been lost,⁶ so the relatively caudal position of the bronchial bifurcation does not cause any breathing impediment. In our cases notwithstanding ability of neck retraction, the carina positioned more caudally than that of the land turtles. In this study, however, we observed that the long trachea was positioned ventral and to the left of the neck. It seems that the left replacement of the lengthened trachea in the European pond turtle is a kind of accommodation to prevent the pressing of the trachea by the neck and underlying hard tissues during the retraction.

It has been stated that the intrapulmonary bronchus of the chelonians has no branching.⁹ It courses in the pulmonary tissue as a central airway and branches off terminal minor bronchioles for the pulmonary chambers.¹⁰ In our study the CT images showed accurately branching off the main bronchus into the caudal and dorsal branches which coursed in the respective direction to ventilate the lungs by the terminal minor bronchioles.

In the *Emys orbicularis* like other chelonians, lungs are paired and have typical reticular or honeycomb pattern. They were not surrounded by a pleural cavity and were attached dorsally to the carapace, which coincided with observations made for the chelonians.^{11, 12} In our study, in some areas the lungs were seen at a superficial position after remove of the ventral body wall and

pectoral girdles. This phenomenon disagrees with the Perry, 1989 statement that says "lungs are separated from the ventral cavity and viscera by a thin non-muscular postpulmonary septum".¹¹

It is reported that the lungs volume is reduced to one fifth when the head and limbs are retracted.⁷ Our study showed that the neck retraction decrease the lung volume. Examination of the CT images of the protruded and retracted neck revealed that two procedures resulted in this feature: a. the displacement of the lung apices ventrolaterally and b. getting away of the medial borders of the lungs. In addition, the flexion and extension of the pelvic limb can change the position of the caudal extremity of the lung while action of the thoracic limb has no effect on it.

Because of high potential of different organs differentiation, Computed Tomography is said to be an innovative modality in the imaging of the lung for clinical diagnosis in small animals.^{13, 14, 15, 16} Since chelonians are enclosed in a bony shell, their physical examination is limited. Therefore diagnostic imaging can be helpful to gain more complete perspective of their internal organs. In addition, our results offer a baseline for detailed respiratory studies in the chelonians and promote future investigations in this field. This study is the first description of the CT-anatomical features of the lower respiratory system of the *Emys orbicularis*.

References

1. Anderson SC, Synopsis of the turtles, crocodiles and amphiabaenians of Iran. In *Proceeding, California Academy of Sciences*, 1972; 4, 41(22): 501-528.
2. Murray MJ, *Reptile Medicine and Surgery*. Saunders, 1996: 396-405.
3. McArthur S, Wilkinson R, Meyer J. *Medicine and Surgery of Tortoises and Turtles*. Blackwell, 2004: 187-238.
4. De Rycke LM, Gielen IM, Simoens PJ, et al. Computed tomography and cross-sectional anatomy of the thorax in clinically normal dogs. *Am J Vet Res* 2005; 66, 512-524.
5. Samii VF, Biller DS, Koblik PD. Normal cross-sectional anatomy of the feline thorax and abdomen: comparison of computed tomography and cadaver anatomy. *Vet Radiol Ultrasound* 1998; 39, 504-511.
6. Valente AL, Cuenca R, Zamora M, et al. Computed tomography of the vertebral column and coelomic structures in the normal loggerhead sea turtle (*Caretta caretta*). *tvjl* 2007; 174:362-370.
7. Mitchell, MA, *Manual of Exotic Pet Practice*. Saunders, 2009: 207-249.
8. O'Malley B, *Clinical Anatomy and Physiology of Exotic Species*. Saunders, 2005: 41-56.
9. Murray MJ, *Reptile Medicine and Surgery*. Elsevier, 2006: 124-134.
10. Krautwald Junghanns ME, Pees M, Reese S, *Diagnostic Imaging of Exotic Pets*. Schlütersche, 2011: 360-363.
11. Perry SF, *Comparative pulmonary physiology – current concepts*. Dekker, 1989; 193-237.
12. Schwarz T, Saunders J, *Veterinary computed tomography*. Wiley-Blackwell, 2011; 533-544.
13. Johnson VS, Ramsey IK, Thompson H, et al. Thoracic high resolution computed tomography in the diagnosis of metastatic carcinoma. *J Small Anim Pract* 2004;45:134-143.
14. Morandi F, Mattoon JS, Lakritz J, et al. Correlation of helical and incremental high-resolution thin-section computed tomographic and histomorphometric quantitative evaluation of an acute inflammatory response of lungs in dogs. *Am J Vet Res* 2004; 65: 1114-1123.
15. Sajjadian SM, Shojaei B, Molaei MM, Computed Tomographic Anatomy of the Bronchial Tree of the Jebeer Gazelle. *IJVS* 2008; 3(1): 73-80.
16. Zekas LJ, Crawford JT, O'Brien RT. Computed tomography-guided fine-needle aspirate and tissue-core biopsy of intrathoracic lesions in thirty dogs and cats. *Vet Radiol Ultrasound* 2005; 46: 200-204.

چکیده

بررسی کالبد شناختی تصاویر لایه نگاری رایانه‌ای و توپوگرافی بخش پایینی دستگاه تنفس در لاک‌پشت برکه‌ای اروپایی (*Emys orbicularis*)

امید زهتاب ور^۱، زهرا طوطیان^۱، علیرضا وجهی^{۲*}، بهادر شجاعی^۳، امیر رستمی^۴، سمیه داودی پور^۵، جواد صادقی نژاد^۱،
هانیه غفاری^۵، ایمان معماریان^۶

^۱گروه علوم پایه دانشکده دامپزشکی دانشگاه تهران، تهران، ایران.
^۲گروه جراحی و رادیولوژی دانشکده دامپزشکی دانشگاه تهران، تهران، ایران.
^۳گروه علوم پایه دانشکده دامپزشکی دانشگاه شهید باهنر، کرمان، ایران.
^۴گروه بیماری‌های داخلی دانشکده دامپزشکی دانشگاه تهران، تهران، ایران.
^۵گروه محیط زیست دانشکده منابع طبیعی دانشگاه کردستان، سنندج، ایران.
^۶دامپزشک حیات وحش، دامپزشک مسئول باغ وحش ارم و مرکز بازپروری پارک پردیسان، تهران، ایران.

هدف - این مطالعه با هدف ارائه اطلاعات کامل توپوگرافی و شیوه قرارگیری ریه‌ها و نای در لاک‌پشت برکه‌ای اروپایی با استفاده از روش لایه‌نگاری رایانه‌ای (سی تی اسکن) و روش‌های معمول کالبدشناسی انجام شد.

طرح مطالعه - مطالعه تجربی

حیوانات - ده لاک‌پشت برکه‌ای اروپایی ماده بالغ

روش کار - تمامی اسکن‌ها به وسیله اسکنر دو دتکتوره انجام شد. در بررسی‌های کالبدشناسی هشت لاک‌پشت تشریح شدند و دو نمونه دیگر به صورت عرضی برش خوردند.

نتایج - در مطالعات ما تفاوت‌هایی در طول نای و محل قرارگیری دو شاخه شدن نای با سایر گونه‌ها مشاهده شد. علاوه بر این در این مقاله توپوگرافی ریه‌ها در دو حالت جمع شده و باز گردن توصیف شد.

نتیجه گیری و کاربرد بالینی - بیشتر دستگاه‌های حیاتی مانند ریه‌ها و بخش داخل سلومی نای، در داخل فضای محفوظ لاک قرار گرفته‌اند و به همین دلیل به طور عادی توسط دامپزشکان قابل معاینه نیستند. روش‌های غیر تهاجمی تصویر برداری تشخیصی فراهم کننده اطلاعات دقیق مربوط به این اندام‌ها هستند. در این مطالعه نمای عمومی بخش پایینی دستگاه تنفس لاک‌پشت برکه‌ای اروپایی به وسیله تصاویر لایه‌نگاری رایانه‌ای و به صورت ماکروسکوپی مورد بررسی قرار گرفت و تفاوت‌های مهمی با سایر گونه‌ها یافت شد.
کلمات کلیدی - لایه‌نگاری رایانه‌ای، کالبدشناسی، توپوگرافی، ریه، نای، لاک‌پشت برکه‌ای اروپایی.